Handbook of Clinical Neurology, Vol. 92 (3rd series)
Stroke, Part I
M. Fisher, Editor
© 2009 Elsevier B.V. All rights reserved

Chapter 13

Anatomy of the circulation of the brain and spinal cord

LAURENT TATU [1,2]*, FABRICE VUILLIER [1,2], AND THIERRY MOULIN [2]

[1]*Laboratoire d'Anatomie, Faculté de Médecine, Université de Franche-Comté, Besançon, France*

[2]*Service de Neurologie, Centre Hospitalier Universitaire Jean Minjoz, Besançon, France*

Tatu et al. 2009

CEREBELO

1. Vertebral artery
2. Anterior spinal artery
3. Posterior inferior cerebellar artery
4. Basilar artery
5. Anterior inferior cerebellar artery
6. Superior cerebellar artery
7. Posterior cerebral artery
8. Collicular artery
9. Posteromedial choroidal artery
10. Anterior choroidal artery
11. Anteromedial group of medullary arteries
12. Anterolateral group of medullary arteries
13. Lateral group of medullary arteries (a. inferior rami arising from the posterior inferior cerebellar artery; b. middle rami arising from the vertebral artery; c. superior rami arising from the anterior inferior cerebellar artery)
14. Anteromedial group of pontine arteries penetrating the basilar sulcus (14′ arteries penetrating the foramen coecum; 14′′ arteries penetrating the interpeduncular fossa, inferior rami of the interpeduncular fossa)
15. Anterolateral group of pontine arteries
16. Lateral group of pontine arteries
17. Anteromedial group of mesencephalic arteries (middle rami of the interpeduncular fossa)
18. Anterolateral group of mesencephalic arteries (superior rami of the interpeduncular fossa)
19. Lateral group of mesencephalic arteries
20. Branches of the superior cerebellar artery
21. Branches of the anterior inferior cerebellar artery
22. Branches of the posterior inferior cerebellar artery

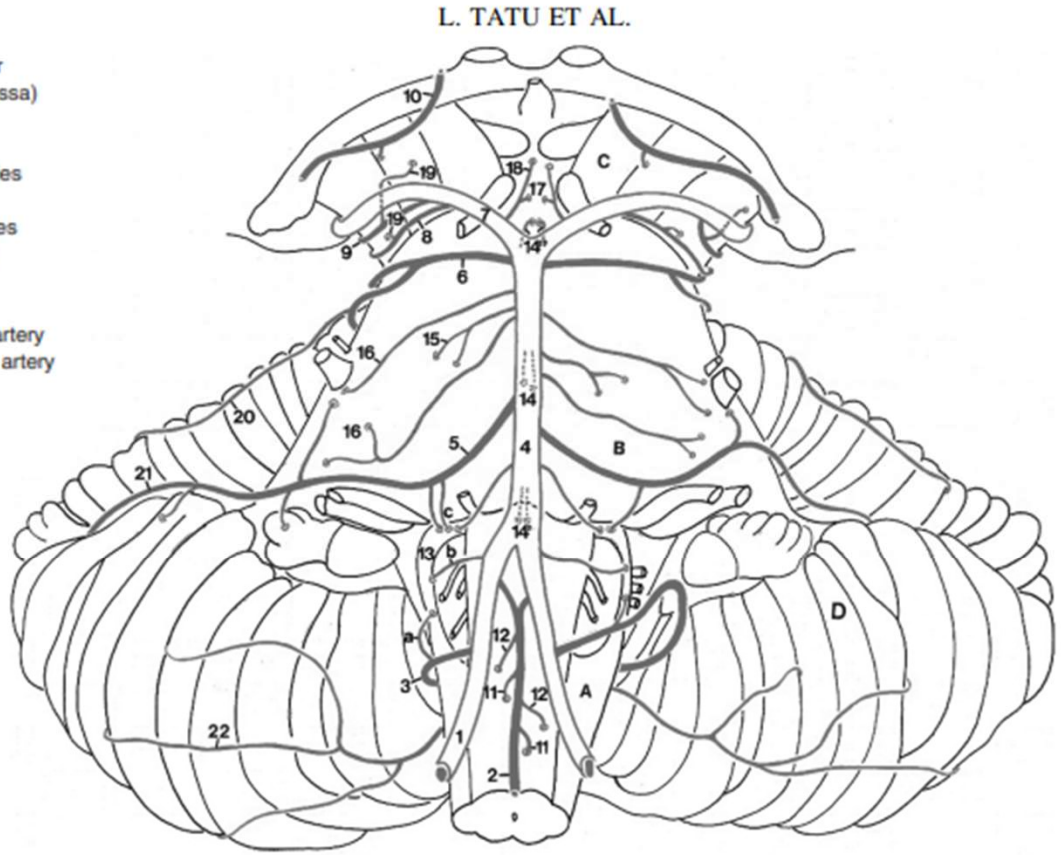

CORONAL - HEMISFÉRIO

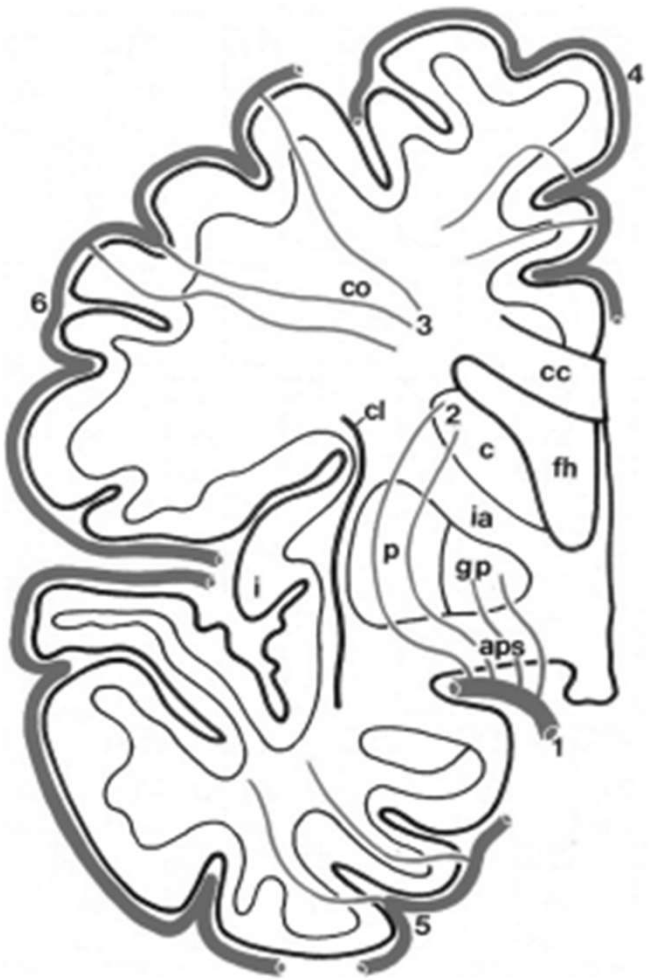

1. Middle cerebral artery
2. Perforating arteries (deep perforating arteries)
3. Medullary arteries (superficial perforating arteries)
4. Leptomeningeal branches of the anterior cerebral artery
5. Leptomeningeal branches of the posterior cerebral artery
6. Leptomeningeal branches of the middle cerebral artery

CÍRCULO DE WILLIS

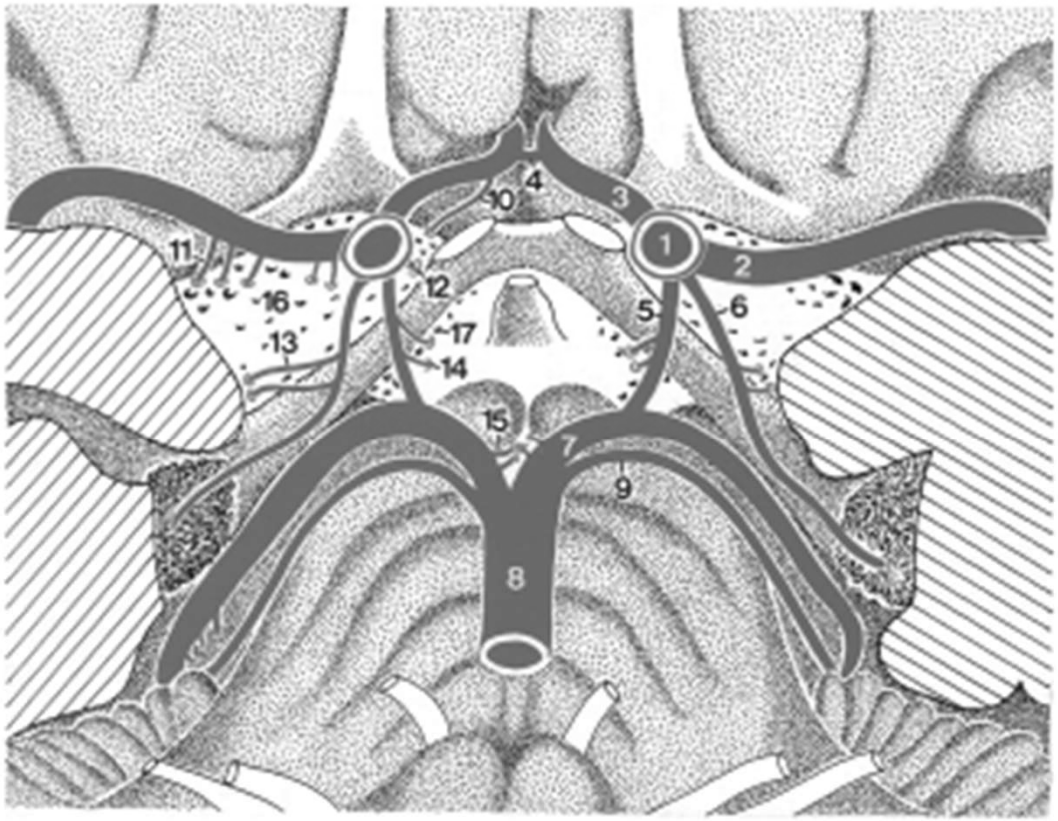

. 13.3. The arterial circle of Willis.

1. Internal carotid artery
2. Middle cerebral artery
3. Anterior cerebral artery
4. Anterior communicating artery
5. Posterior communicating artery
6. Anterior choroidal artery
7. Posterior cerebral artery
8. Basilar artery
9. Superior cerebellar artery
10. Recurrent artery of Heubner
11. Middle cerebral artery perforating branches
12. Internal carotid artery perforating branches
13. Anterior choroidal artery perforating branches
14. Posterior communicating artery perforating branches
15. Posterior cerebral artery perforating branches
16. Anterior perforated substance
17. Lateral perforated substance

AXIAL - TRONCO

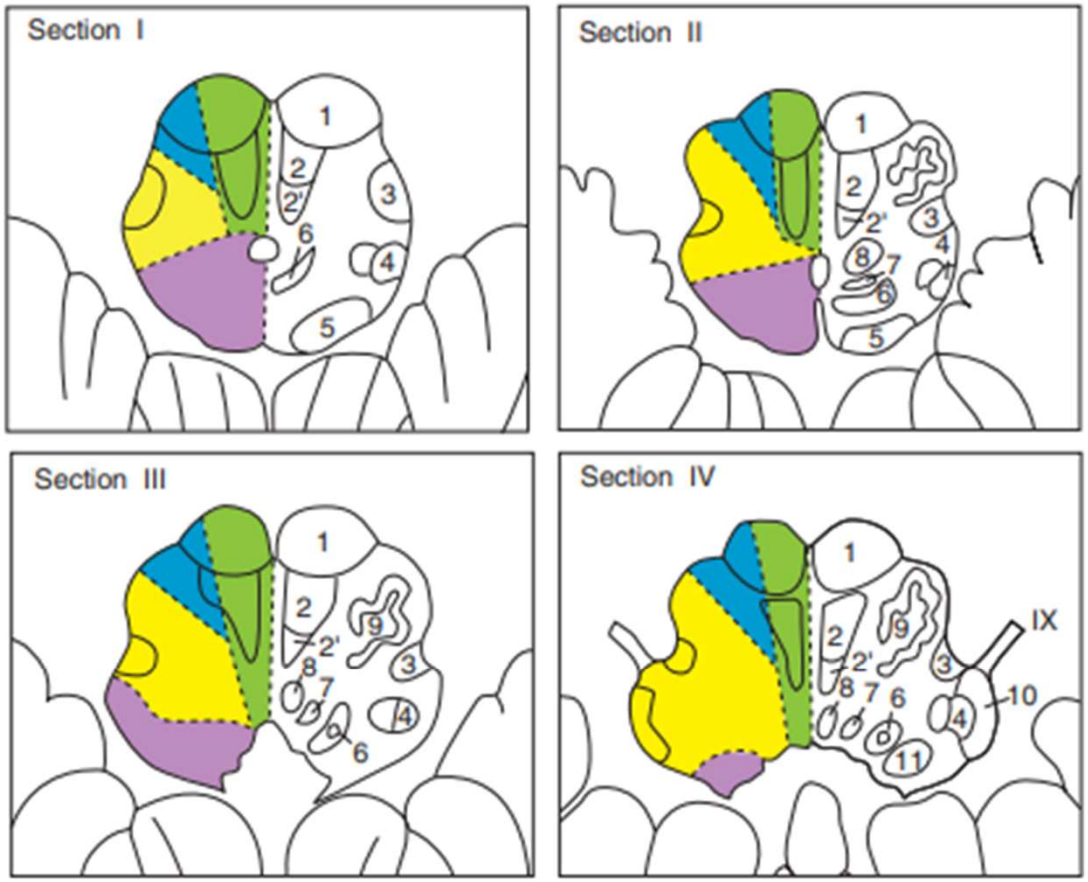

1	Corticospinal tract
2	Medial lemniscus
2′	Medial longitudinal fasciculus
3	Spinothalamic tract
4	Spinal trigeminal tract and nuclei
5	Gracile and cuneate nuclei
6	Nucleus of the solitary tract
7	Dorsal motor vagal nucleus
8	Hypoglossal nucleus
9	Inferior olivary nucleus
10	Inferior cerebellar peduncle
11	Vestibular nucleus
12	Nucleus prepositus
13	Facial nucleus
14	Superior olivary nucleus
15	Abducens nucleus

Anteromedial group

Anterolateral group

Lateral group

Posterior group

AXIAL - TRONCO

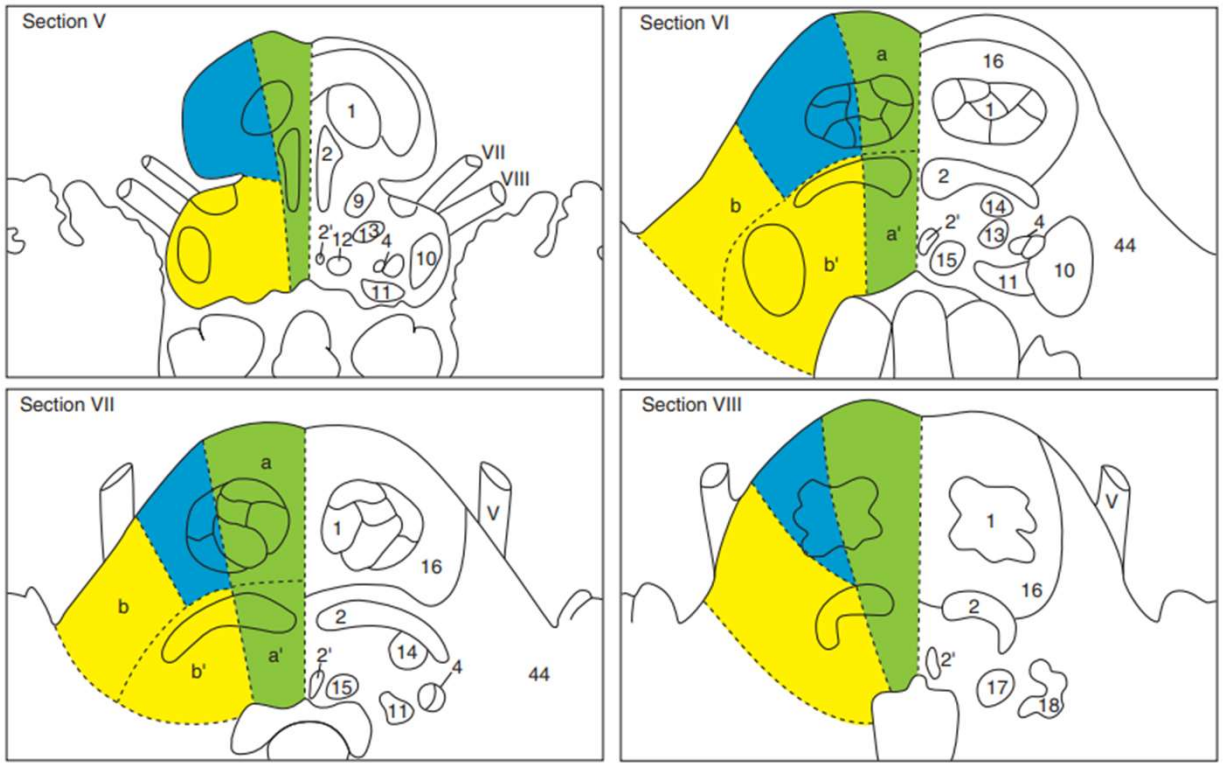

1	Corticospinal tract
2	Medial lemniscus
2′	Medial longitudinal fasciculus
3	Spinothalamic tract
4	Spinal trigeminal tract and nuclei
10	Inferior cerebellar peduncle
11	Vestibular nucleus
12	Nucleus prepositus
13	Facial nucleus
14	Superior olivary nucleus
15	Abducens nucleus
16	Pontine nuclei
17	Motor trigeminal nucleus
18	Principal sensory trigeminal nucleus
19	Nucleus ceruleus
20	Superior cerebellar peduncle
21	Substantia nigra
22	Inferior colliculus
23	Trochlear nucleus
24	Superior colliculus

Anteromedial group

Anterolateral group

Lateral group

Posterior group

AXIAL - TRONCO

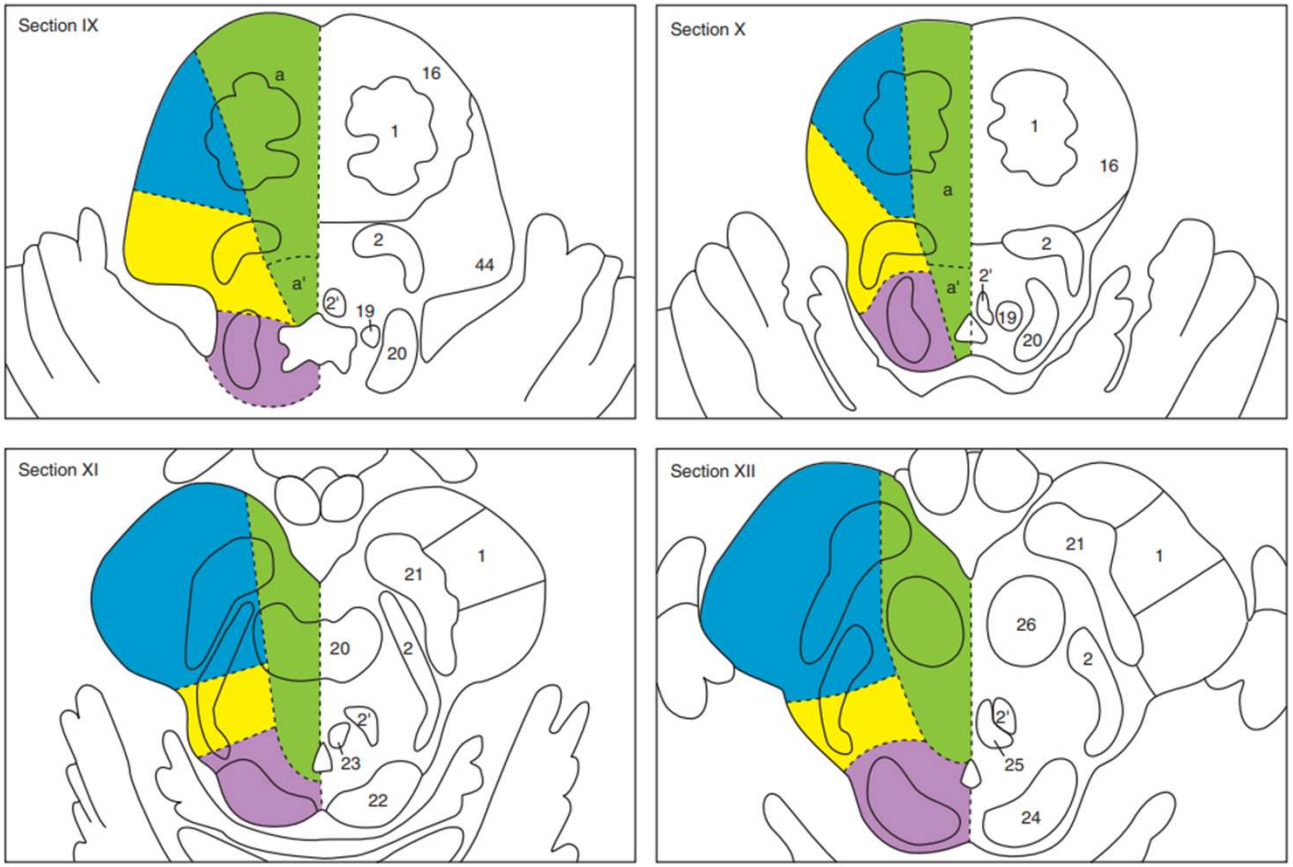

1	Corticospinal tract
2	Medial lemniscus
2′	Medial longitudinal fasciculus
3	Spinothalamic tract
14	Superior olivary nucleus
15	Abducens nucleus
16	Pontine nuclei
17	Motor trigeminal nucleus
18	Principal sensory trigeminal nucleus
19	Nucleus ceruleus
20	Superior cerebellar peduncle
21	Substantia nigra
22	Inferior colliculus
23	Trochlear nucleus
24	Superior colliculus
25	Oculomotor nucleus
26	Red nucleus
27	Mammillary body
28	Optic tract
29	Lateral geniculate body

Anteromedial group

Anterolateral group

Lateral group

Posterior group

AXIAL - CEREBELO

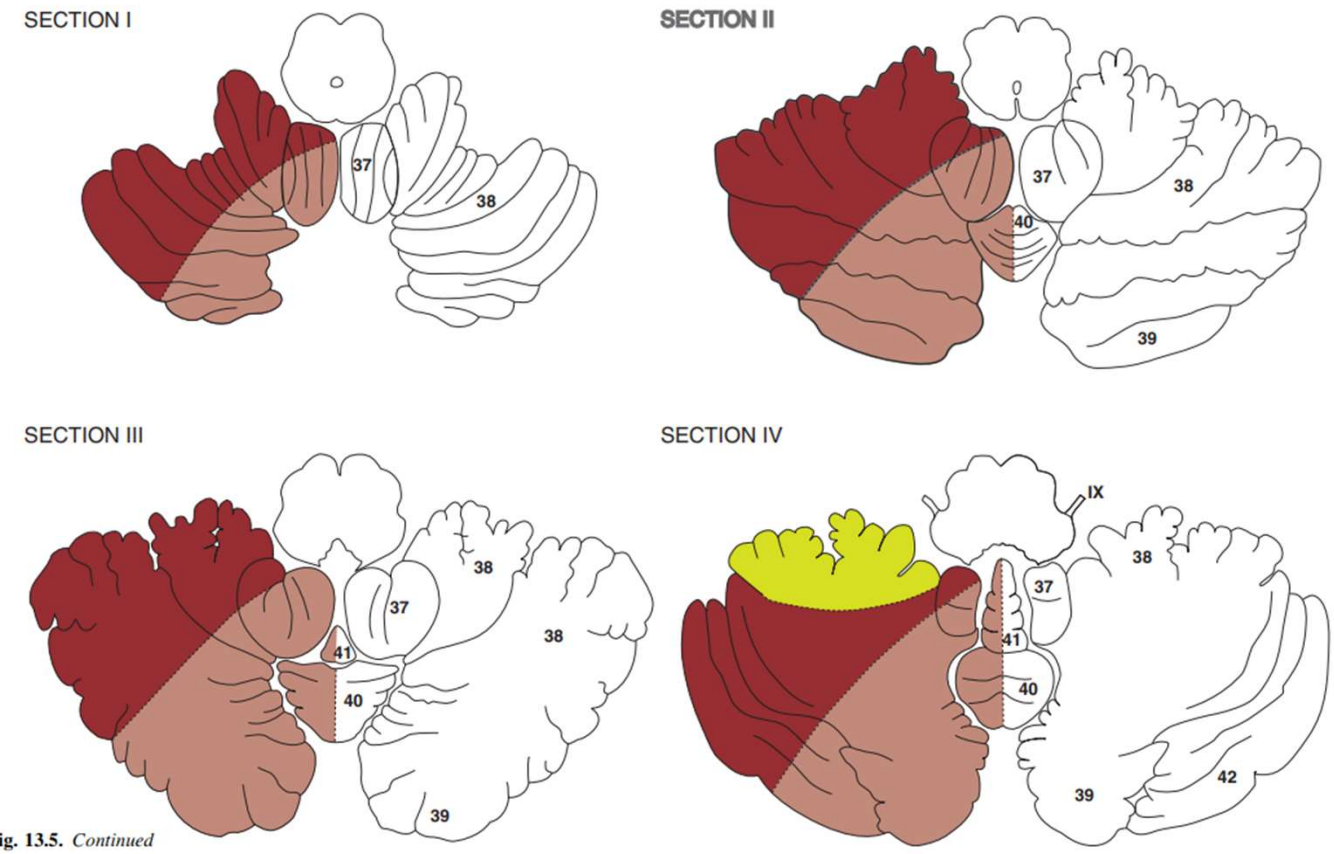

Fig. 13.5. *Continued*

37	Tonsil
38	Biventer lobule
39	Inferior semilunar lobule
40	Pyramid of vermis
41	Uvula
42	Superior semilunar lobule
43	Tuber of vermis
44	Middle cerebellar peduncle
45	Dentate nucleus
46	Folium of vermis
47	Nodulus
48	Flocculus
49	Declive
50	Simple lobule
51	Culmen
52	Quadrangular lobule
53	Central lobule
54	Ala of the central lobule

Cerebellar territories

- Lateral branch of the posterior inferior cerebellar artery
- Medial branch of the posterior inferior cerebellar artery
- Lateral branch of the superior cerebellar artery
- Medial branch of the superior cerebellar artery
- Anterior inferior cerebellar artery

AXIAL - CEREBELO

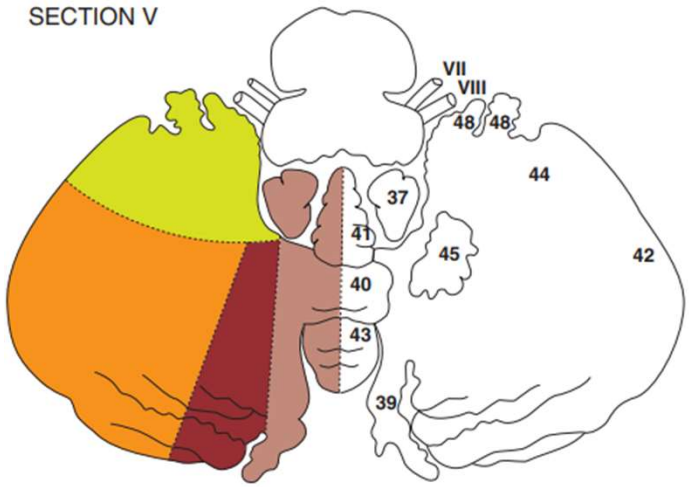

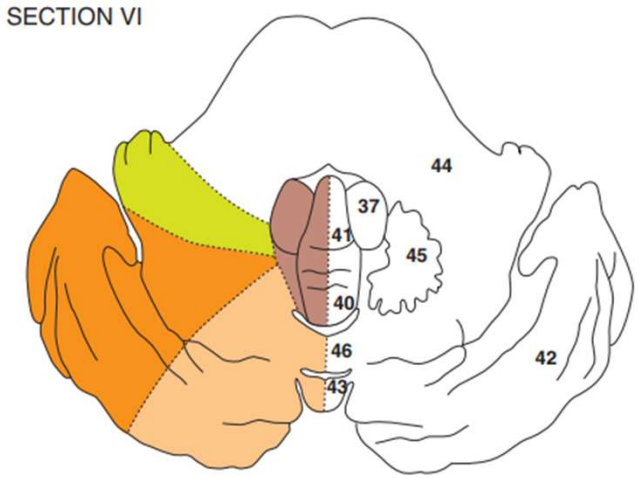

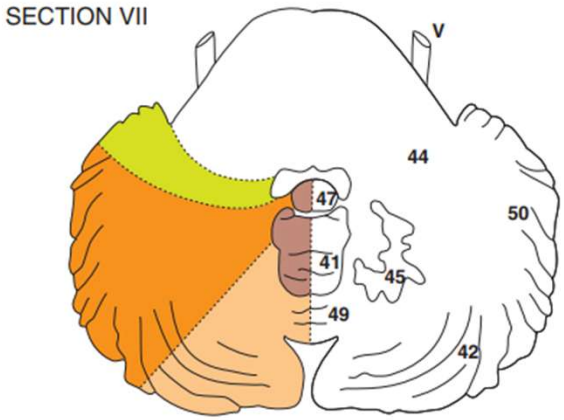

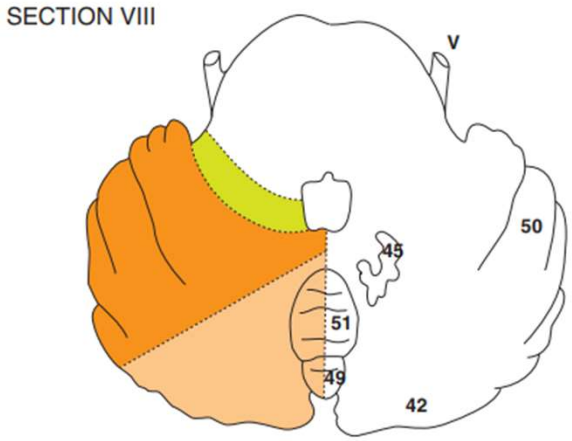

37	Tonsil
38	Biventer lobule
39	Inferior semilunar lobule
40	Pyramid of vermis
41	Uvula
42	Superior semilunar lobule
43	Tuber of vermis
44	Middle cerebellar peduncle
45	Dentate nucleus
46	Folium of vermis
47	Nodulus
48	Flocculus
49	Declive
50	Simple lobule
51	Culmen
52	Quadrangular lobule
53	Central lobule
54	Ala of the central lobule

Cerebellar territories

- Lateral branch of the posterior inferior cerebellar artery
- Medial branch of the posterior inferior cerebellar artery
- Lateral branch of the superior cerebellar artery
- Medial branch of the superior cerebellar artery
- Anterior inferior cerebellar artery

AXIAL - CEREBELO

SECTION IX

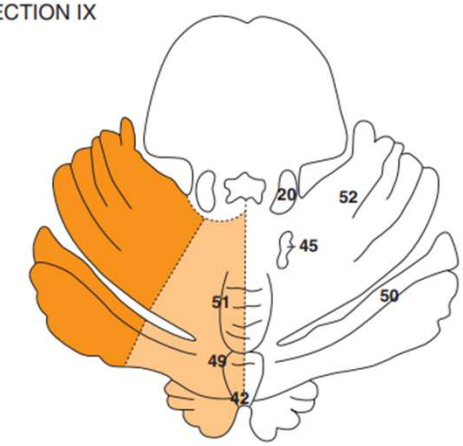

SECTION X

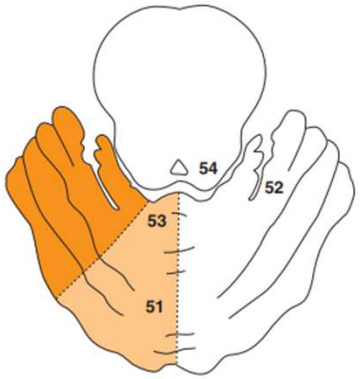

SECTION XI

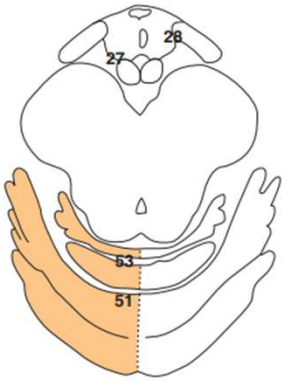

SECTION XII

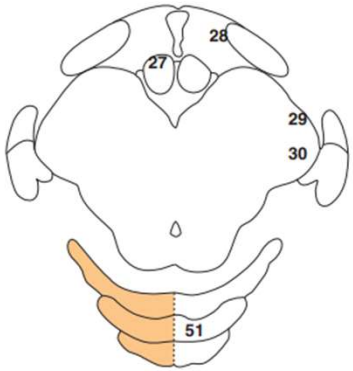

20	Superior cerebellar peduncle
24	Superior colliculus
25	Oculomotor nucleus
26	Red nucleus
27	Mammillary body
28	Optic tract
29	Lateral geniculate body
30	Medial geniculate body
31	Pulvinar
32	Mammillothalamic tract
33	Column of fornix
34	Caudate nucleus
35	Putamen
36	Anterior commissure
37	Tonsil
38	Biventer lobule
39	Inferior semilunar lobule
40	Pyramid of vermis
41	Uvula
42	Superior semilunar lobule
43	Tuber of vermis
44	Middle cerebellar peduncle
45	Dentate nucleus
46	Folium of vermis
47	Nodulus
48	Flocculus
49	Declive
50	Simple lobule
51	Culmen
52	Quadrangular lobule
53	Central lobule
54	Ala of the central lobule

Cerebellar territories

- Lateral branch of the posterior inferior cerebellar artery
- Medial branch of the posterior inferior cerebellar artery
- Lateral branch of the superior cerebellar artery
- Medial branch of the superior cerebellar artery
- Anterior inferior cerebellar artery

AXIAL - HEMISFÉRIOS

Anatomical structures of the cerebral hemispheres (sections XIII–XXIV)

Gyri (purple)

CG	Cingulate gyrus
F1	Superior frontal gyrus
F2	Middle frontal gyrus
F3	Inferior frontal gyrus
F3op	Inferior frontal gyrus pars opercularis
F3or	Inferior frontal gyrus pars orbitalis
F3t	Inferior frontal gyrus pars triangularis
FMG	Frontomarginal gyrus
GR	Gyrus rectus
LOG	Lateral orbital gyrus
MOG	Medial orbital gyrus
PCu	Precuneus
POG	Posterior orbital gyrus
SCG	Subcallosal gyrus
PCL	Paracentral lobule
PoCG	Postcentral gyrus
PrCG	Precentral gyrus
AG	Angular gyrus
P1	Superior parietal gyrus
P2	Inferior parietal gyrus
SMG	Supramarginalis gyrus
T1	Superior temporal gyrus
T2	Middle temporal gyrus
T3	Inferior temporal gyrus
T4	Fusiform gyrus
T5	Parahippocampal gyrus
TTG	Transverse temporal gyrus
O1	Superior occipital gyrus
O2	Middle occipital gyrus
O3	Inferior occipital gyrus
O4	Fusiform gyrus
O5	Lingual gyrus
O6	Cuneus
GD	Gyrus descendens (Ecker)
RSG	Retrosplenial gyrus

Sulci (brown)

AOS	Anterior occipital sulcus
CaS	Calcarine sulcus
CiS	Cingulate sulcus
CoS	Collateral sulcus
CS	Central sulcus
IFS	Inferior frontal sulcus
IOS	Intra-occipital sulcus (superior occipital sulcus)
IPS	Intraparietal sulcus
LF	Lateral fissure
LS	Lingual sulcus
OS	Olfactory sulcus
PCS	Paracentral sulcus
PoCS	Postcentral sulcus
POF	Parieto-occipital fissure
PrCS	Precentral sulcus
RCS	Retrocalcarine sulcus
SFS	Superior frontal sulcus
SPS	Subparietal sulcus
STS	Superior temporal sulcus (parallel sulcus)
TOS	Transverse occipital sulcus

Internal structures (green)

CN	Caudate nucleus
CNh	Caudate nucleus, head
CNt	Caudate nucleus, tail
IA	Internal capsule, anterior limb
IG	Internal capsule, genu
IP	Internal capsule, posterior limb
NA	Nucleus accumbens
P	Putamen
PL	Globus pallidus, pars lateralis
PM	Globus pallidus, pars medialis
SN	Septal nuclei
A	Anterior thalamic nucleus
CM	Centromedian thalamic nucleus
DM	Dorsomedial thalamic nucleus
LD	Lateral dorsal thalamic nucleus
LP	Lateral posterior thalamic nucleus
Pu	Pulvinar
VA	Ventral anterior thalamic nucleus
VL	Ventral lateral thalamic nucleus
VPL	Ventral posterolateral thalamic nucleus
C	Claustrum
CR	Corona radiata
IN	Insula
LI	Limen insulae
CC	Corpus callosum
F	Fornix
Hb	Hippocampus, body
Hh	Hippocampus, head
Ht	Hippocampus, tail
AC	Anterior commissure
Amg	Amygdala
APS	Anterior perforated substance
CrC	Crus cerebri
GA	Gyrus ambiens
H	Hypothalamus
LB	Lateral geniculate body
M	Mammillary body
MB	Medial geniculate body
MT	Mammillothalamic tract
OR	Optic radiations
OT	Olfactory tract
ST	Subthalamic nucleus
T	Tuber

Brodmann's areas (blue).
Colors refer to usual colors used in anatomy illustration.

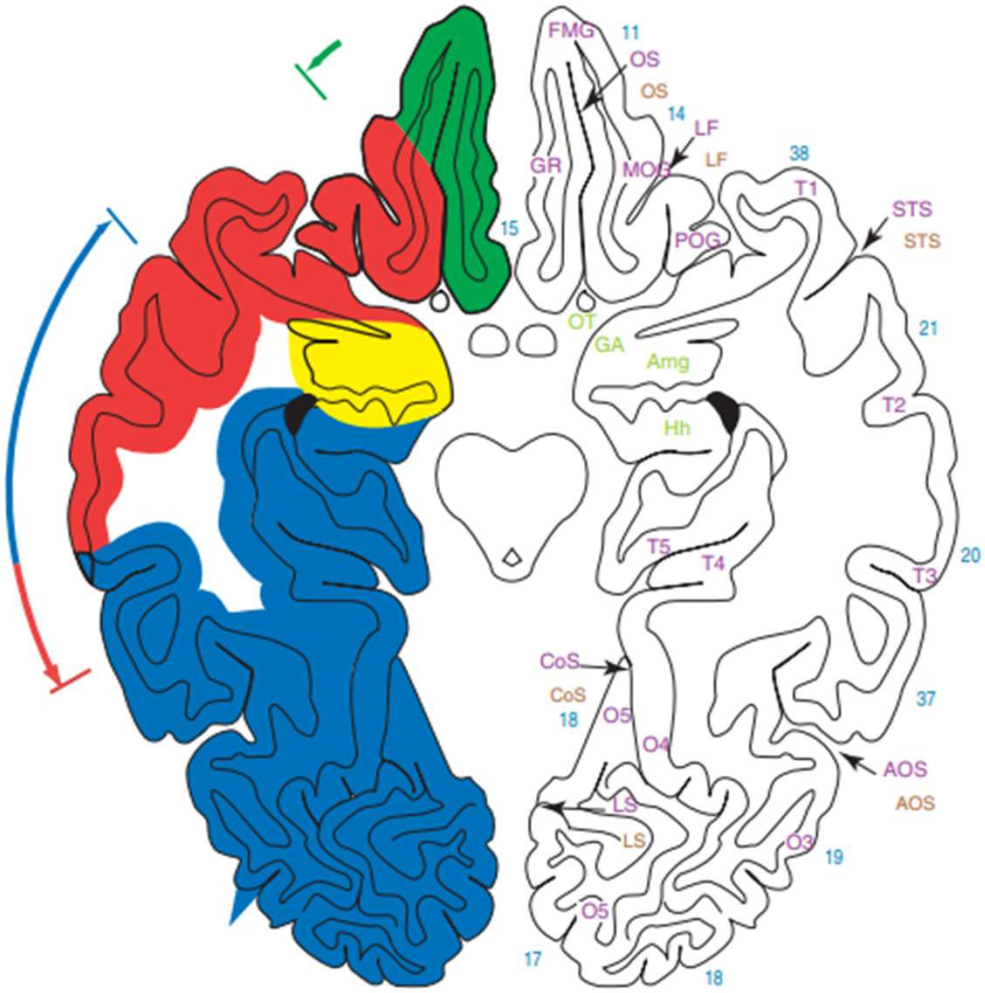

AXIAL - HEMISFÉRIOS

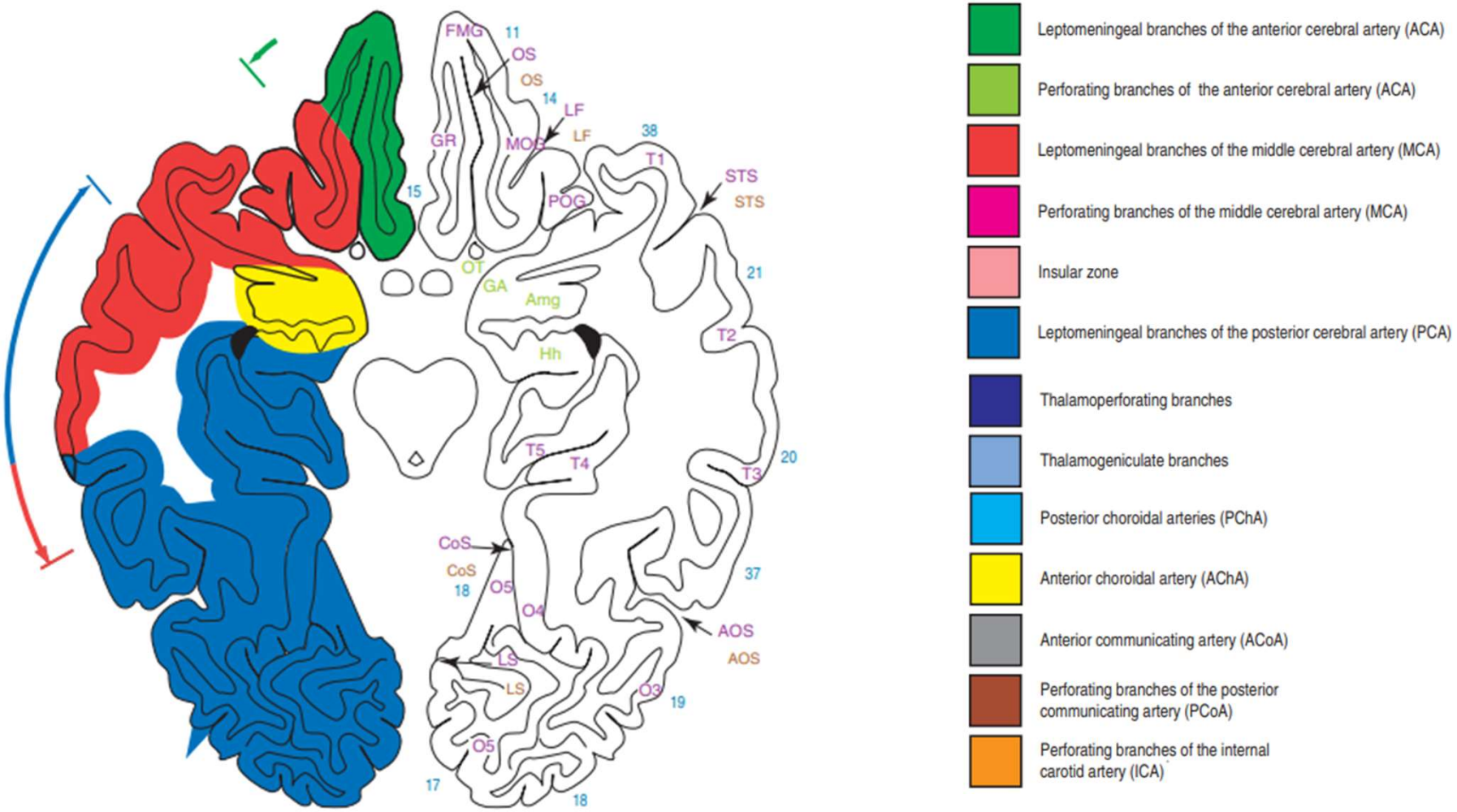

AXIAL - HEMISFÉRIOS

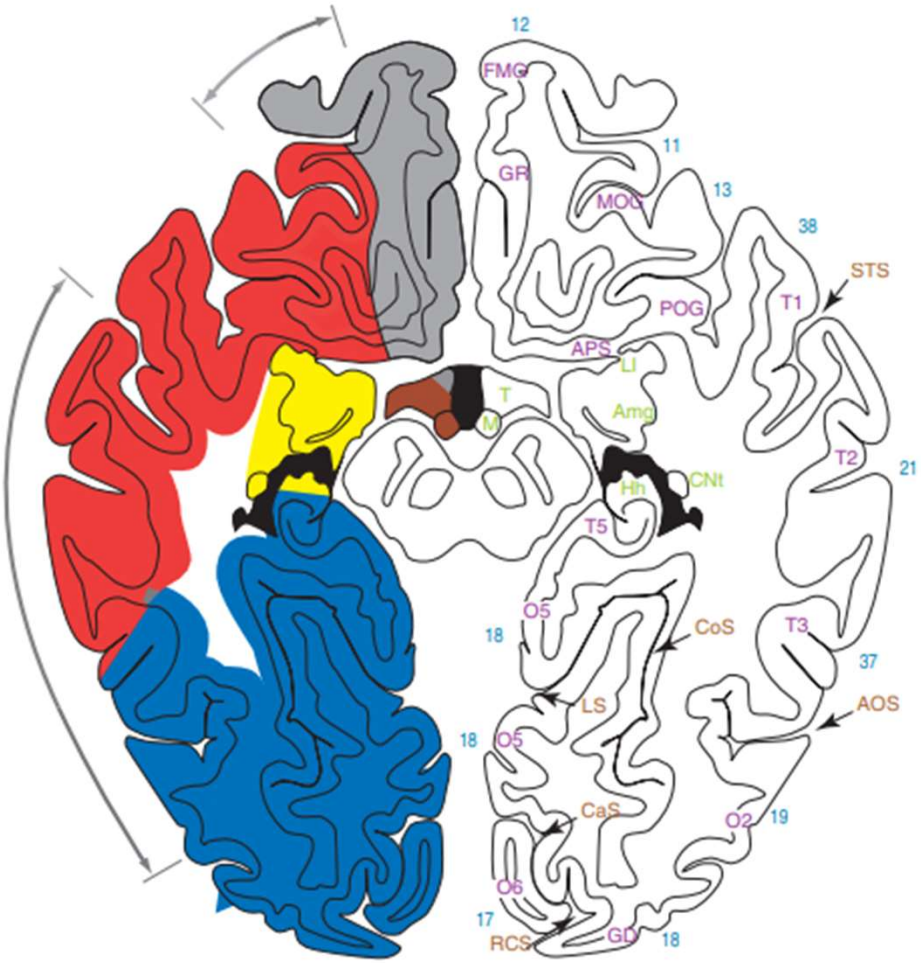

- Leptomeningeal branches of the anterior cerebral artery (ACA)
- Perforating branches of the anterior cerebral artery (ACA)
- Leptomeningeal branches of the middle cerebral artery (MCA)
- Perforating branches of the middle cerebral artery (MCA)
- Insular zone
- Leptomeningeal branches of the posterior cerebral artery (PCA)
- Thalamoperforating branches
- Thalamogeniculate branches
- Posterior choroidal arteries (PChA)
- Anterior choroidal artery (AChA)
- Anterior communicating artery (ACoA)
- Perforating branches of the posterior communicating artery (PCoA)
- Perforating branches of the internal carotid artery (ICA)

AXIAL - HEMISFÉRIOS

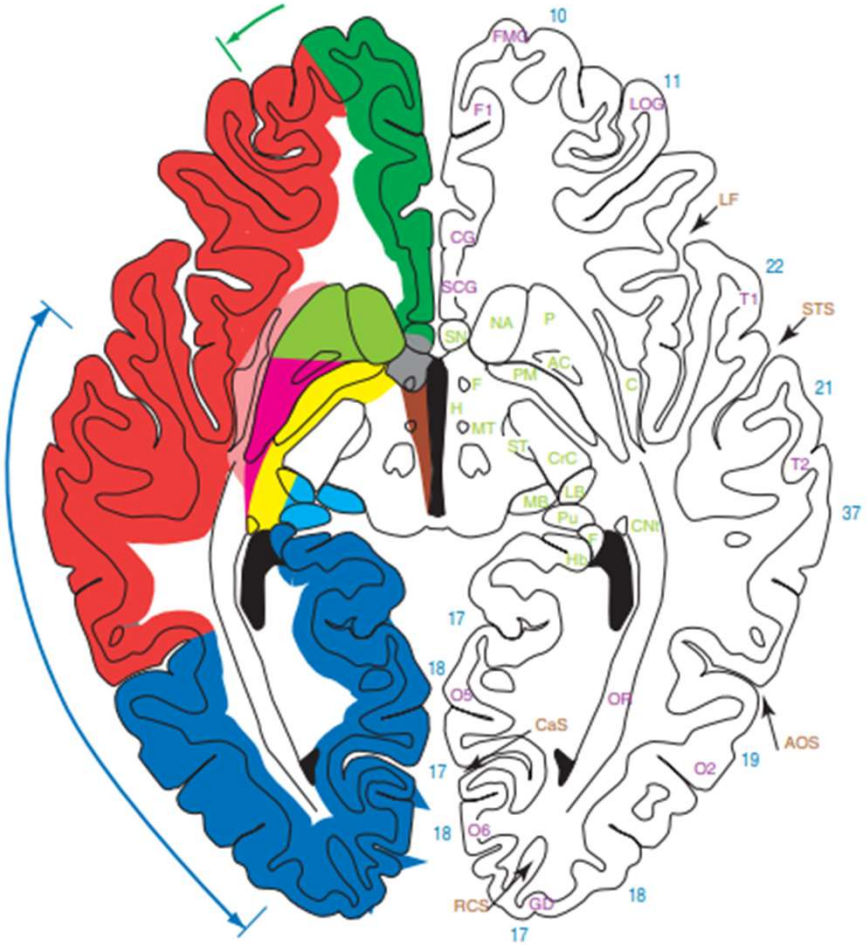

- Leptomeningeal branches of the anterior cerebral artery (ACA)
- Perforating branches of the anterior cerebral artery (ACA)
- Leptomeningeal branches of the middle cerebral artery (MCA)
- Perforating branches of the middle cerebral artery (MCA)
- Insular zone
- Leptomeningeal branches of the posterior cerebral artery (PCA)
- Thalamoperforating branches
- Thalamogeniculate branches
- Posterior choroidal arteries (PChA)
- Anterior choroidal artery (AChA)
- Anterior communicating artery (ACoA)
- Perforating branches of the posterior communicating artery (PCoA)
- Perforating branches of the internal carotid artery (ICA)

AXIAL - HEMISFÉRIOS

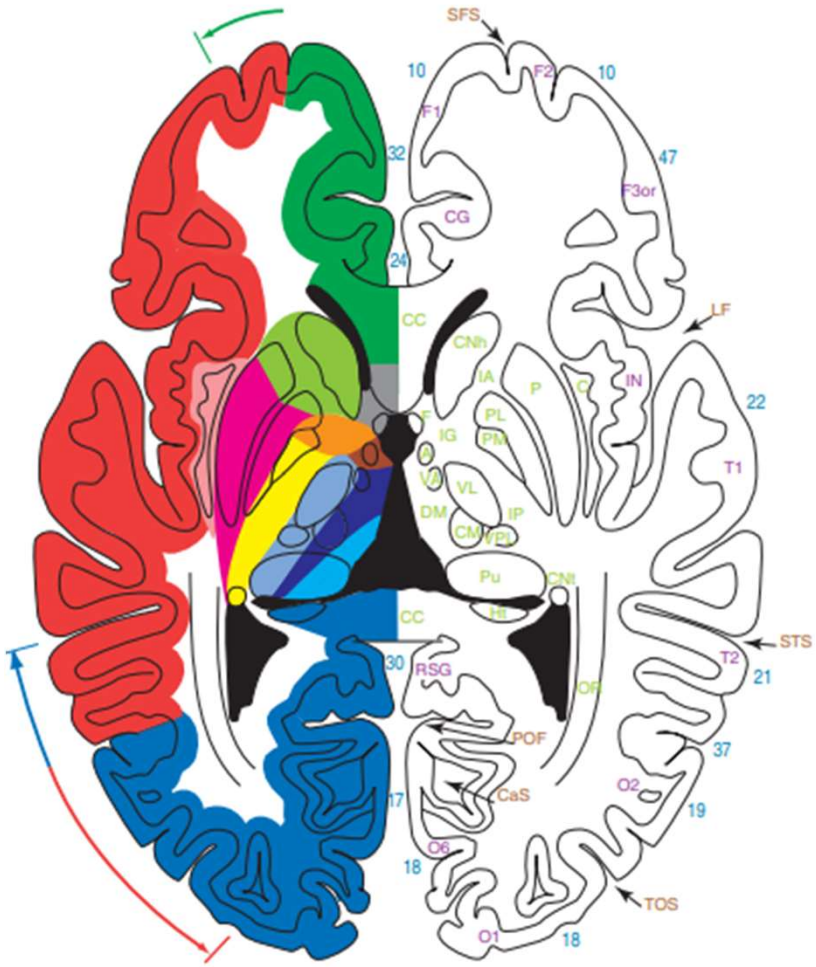

- Leptomeningeal branches of the anterior cerebral artery (ACA)
- Perforating branches of the anterior cerebral artery (ACA)
- Leptomeningeal branches of the middle cerebral artery (MCA)
- Perforating branches of the middle cerebral artery (MCA)
- Insular zone
- Leptomeningeal branches of the posterior cerebral artery (PCA)
- Thalamoperforating branches
- Thalamogeniculate branches
- Posterior choroidal arteries (PChA)
- Anterior choroidal artery (AChA)
- Anterior communicating artery (ACoA)
- Perforating branches of the posterior communicating artery (PCoA)
- Perforating branches of the internal carotid artery (ICA)

AXIAL - HEMISFÉRIOS

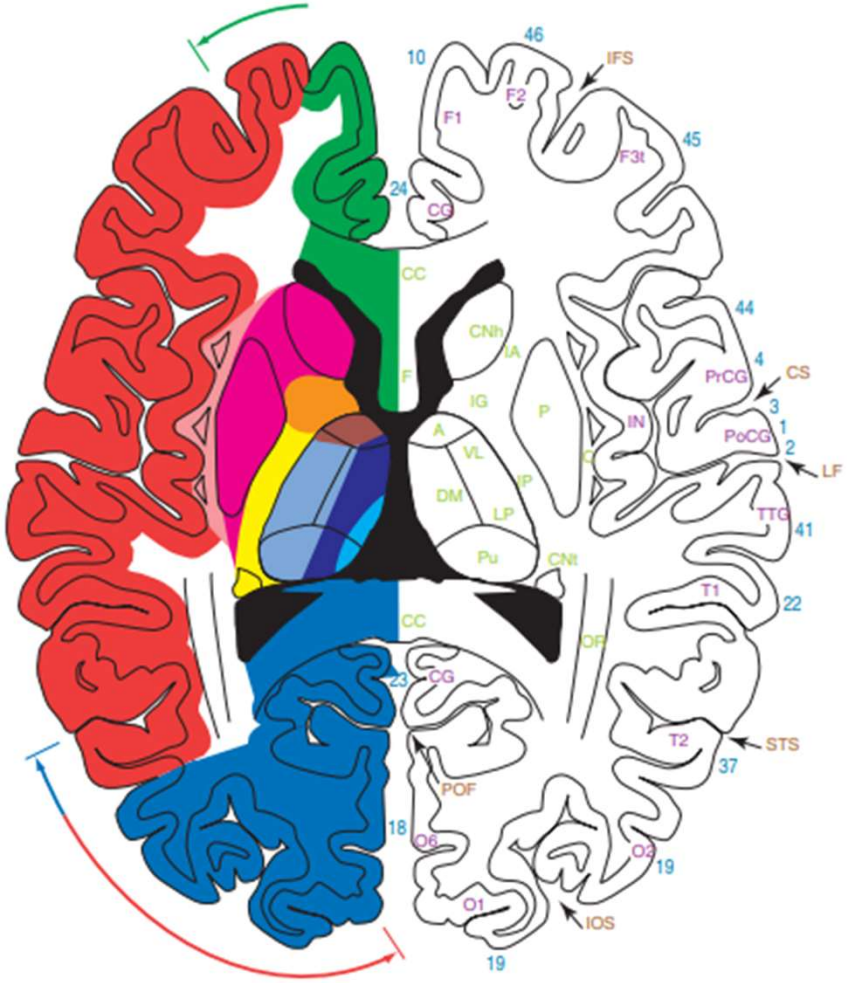

- Leptomeningeal branches of the anterior cerebral artery (ACA)
- Perforating branches of the anterior cerebral artery (ACA)
- Leptomeningeal branches of the middle cerebral artery (MCA)
- Perforating branches of the middle cerebral artery (MCA)
- Insular zone
- Leptomeningeal branches of the posterior cerebral artery (PCA)
- Thalamoperforating branches
- Thalamogeniculate branches
- Posterior choroidal arteries (PChA)
- Anterior choroidal artery (AChA)
- Anterior communicating artery (ACoA)
- Perforating branches of the posterior communicating artery (PCoA)
- Perforating branches of the internal carotid artery (ICA)

AXIAL - HEMISFÉRIOS

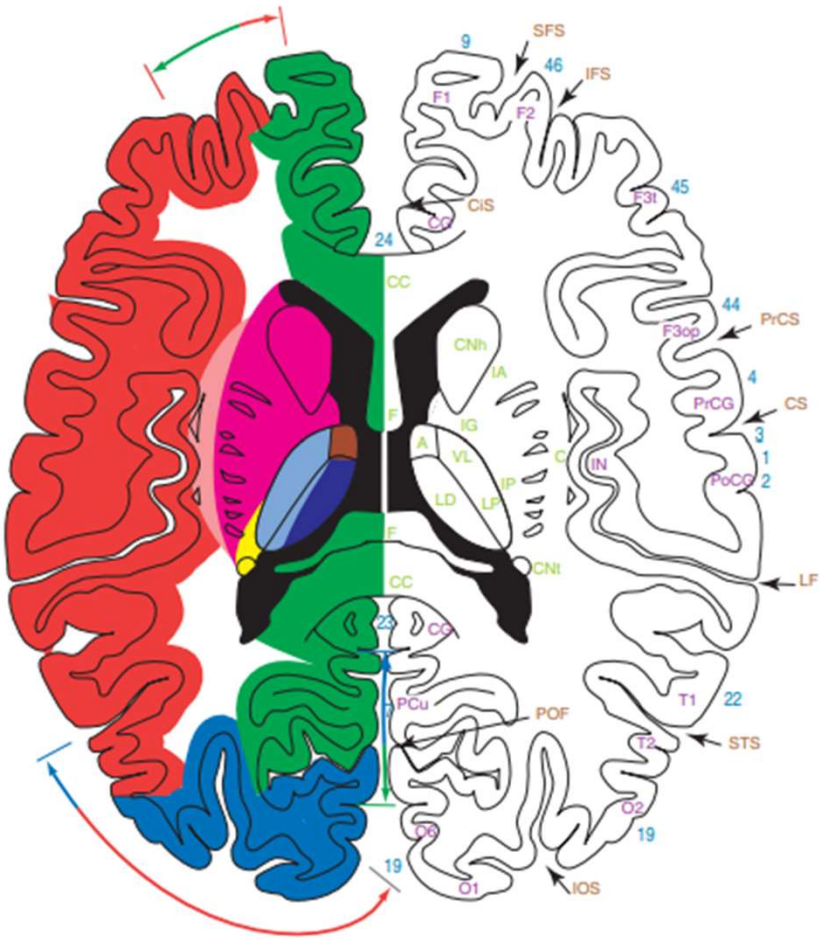

- Leptomeningeal branches of the anterior cerebral artery (ACA)
- Perforating branches of the anterior cerebral artery (ACA)
- Leptomeningeal branches of the middle cerebral artery (MCA)
- Perforating branches of the middle cerebral artery (MCA)
- Insular zone
- Leptomeningeal branches of the posterior cerebral artery (PCA)
- Thalamoperforating branches
- Thalamogeniculate branches
- Posterior choroidal arteries (PChA)
- Anterior choroidal artery (AChA)
- Anterior communicating artery (ACoA)
- Perforating branches of the posterior communicating artery (PCoA)
- Perforating branches of the internal carotid artery (ICA)

AXIAL - HEMISFÉRIOS

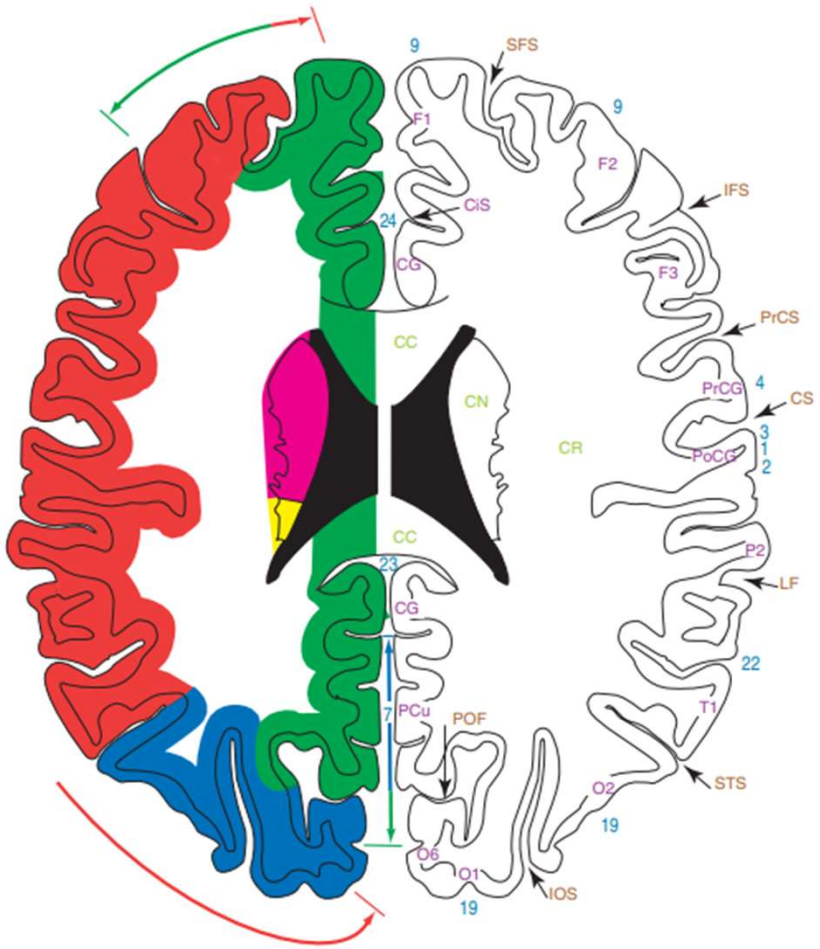

- Leptomeningeal branches of the anterior cerebral artery (ACA)
- Perforating branches of the anterior cerebral artery (ACA)
- Leptomeningeal branches of the middle cerebral artery (MCA)
- Perforating branches of the middle cerebral artery (MCA)
- Insular zone
- Leptomeningeal branches of the posterior cerebral artery (PCA)
- Thalamoperforating branches
- Thalamogeniculate branches
- Posterior choroidal arteries (PChA)
- Anterior choroidal artery (AChA)
- Anterior communicating artery (ACoA)
- Perforating branches of the posterior communicating artery (PCoA)
- Perforating branches of the internal carotid artery (ICA)

AXIAL - HEMISFÉRIOS

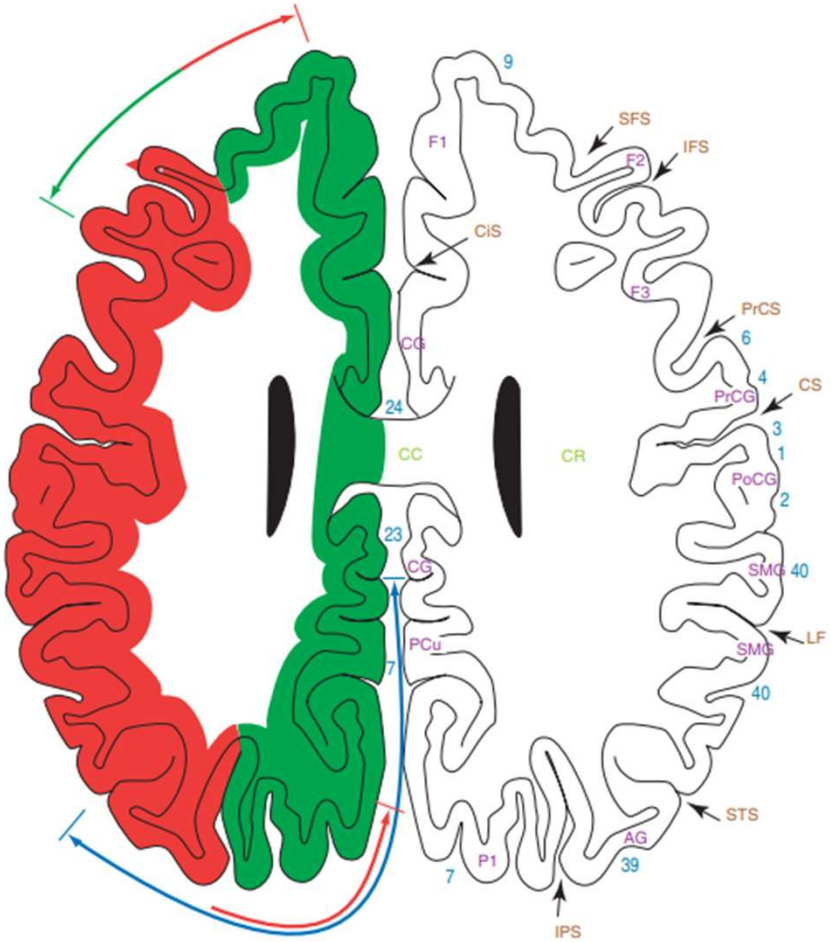

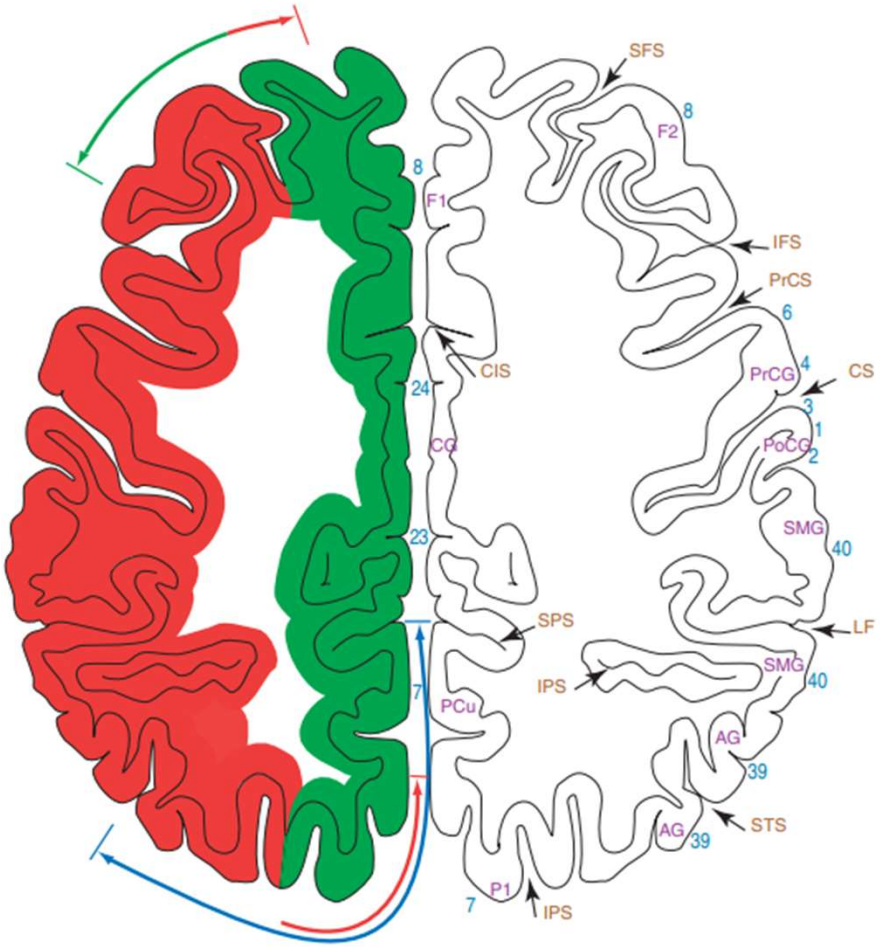

Leptomeningeal branches of the middle cerebral artery (MCA)

Leptomeningeal branches of the anterior cerebral artery (ACA)

AXIAL - HEMISFÉRIOS

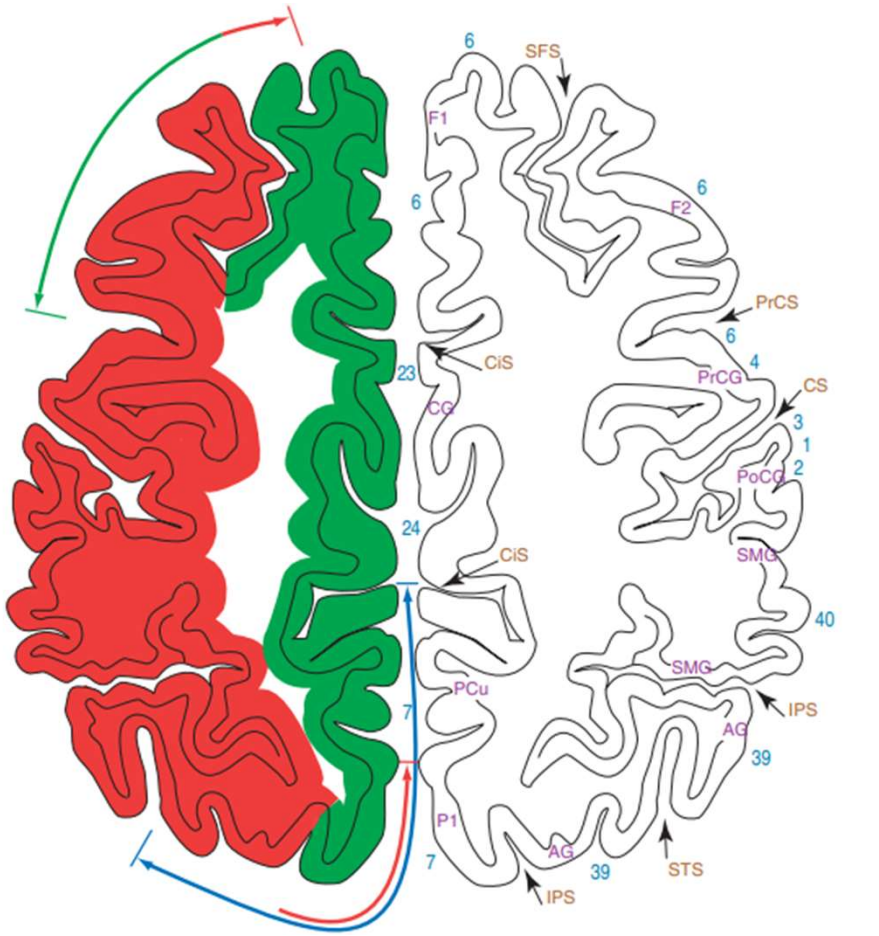

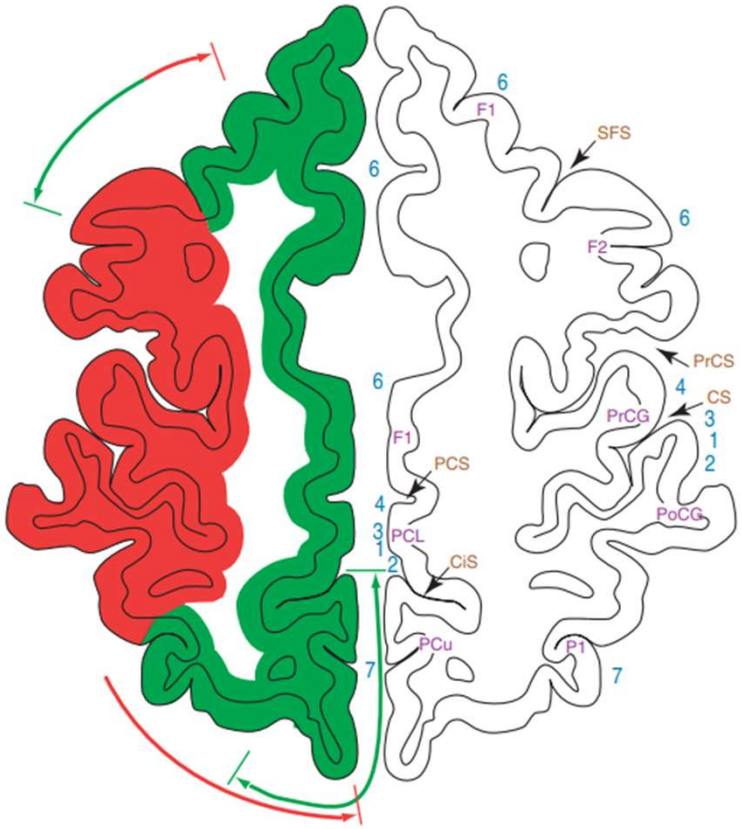

Leptomeningeal branches of the middle cerebral artery (MCA)

Leptomeningeal branches of the anterior cerebral artery (ACA)

AXIAL - HEMISFÉRIOS

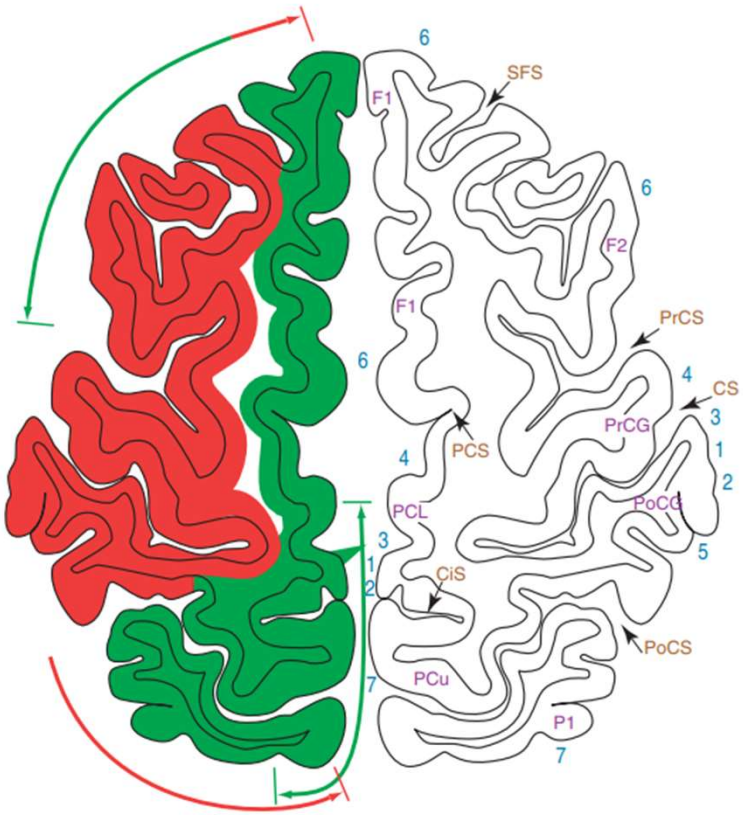

Leptomeningeal branches of the middle cerebral artery (MCA)

Leptomeningeal branches of the anterior cerebral artery (ACA)

SEIOS VENOSOS

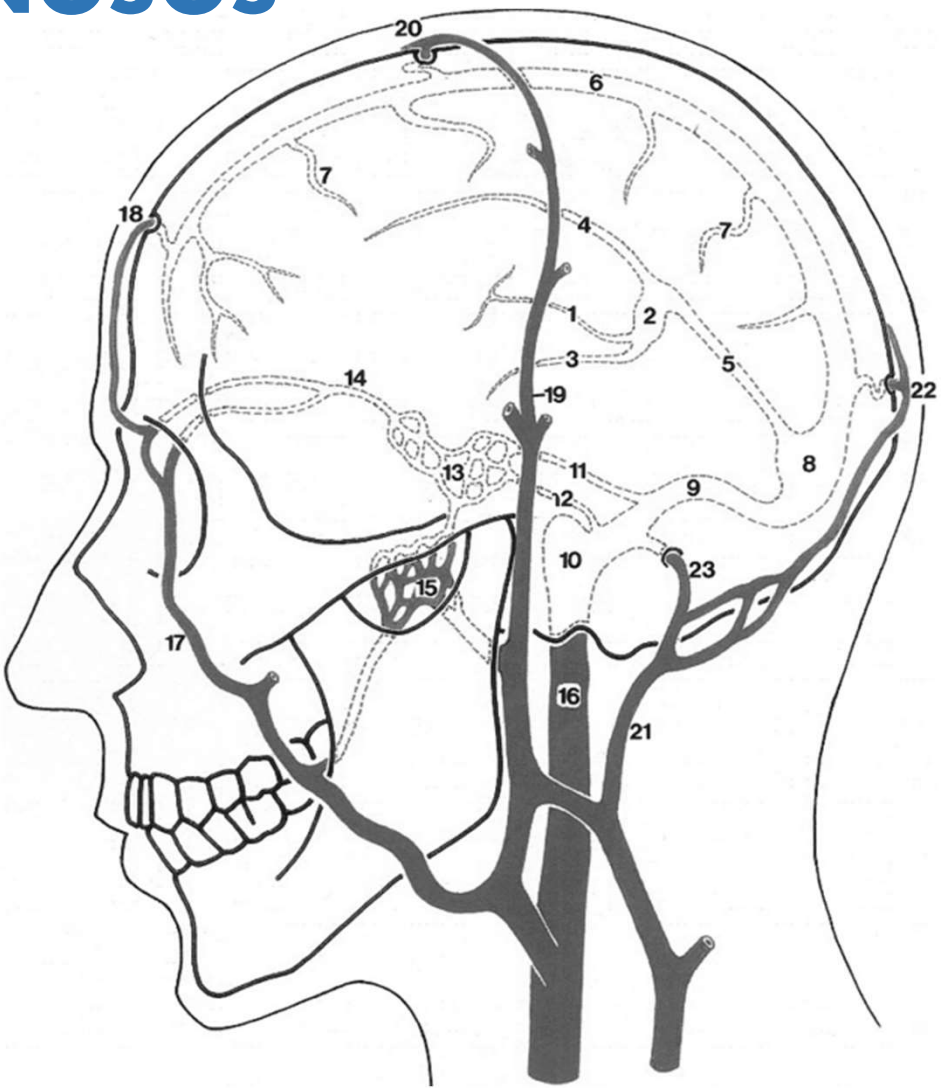

1. Internal cerebral vein
2. Great cerebral vein (of Galen)
3. Basal vein (of Rosenthal)
4. Inferior sagittal sinus
5. Straight sinus
6. Superior sagittal sinus
7. Cortical vein
8. Torcular herophili
9. Lateral sinus
10. Jugular foramen
11. Superior petrosal sinus
12. Inferior petrosal sinus
13. Cavernous sinus
14. Ophthalmic vein
15. Pterygoid plexus
16. Internal jugular vein
17. Facial vein
18. Frontal emissary vein
19. Superficial temporal vein
20. Parietal emissary vein
21. Occipital vein
22. Occipital emissary vein
23. Mastoidal emissary vein

SEIOS VENOSOS

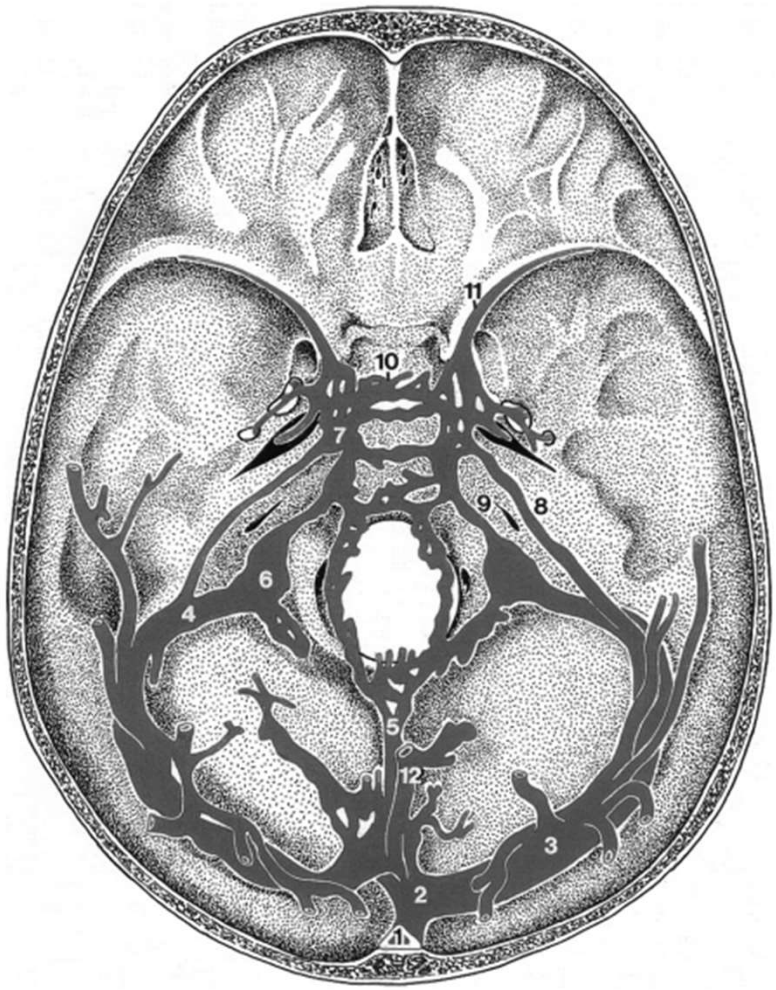

1. Superior sagittal sinus
2. Torcular herophili
3. Lateral sinus
4. Sigmoid sinus
5. Occipital sinus
6. Jugular foramen
7. Cavernous sinus
8. Superior petrosal sinus
9. Inferior petrosal sinus
10. Intercavernous sinus
11. Sphenoparietal sinus
12. Straight sinus

IRRIGAÇÃO ARTERIAL MEDULAR

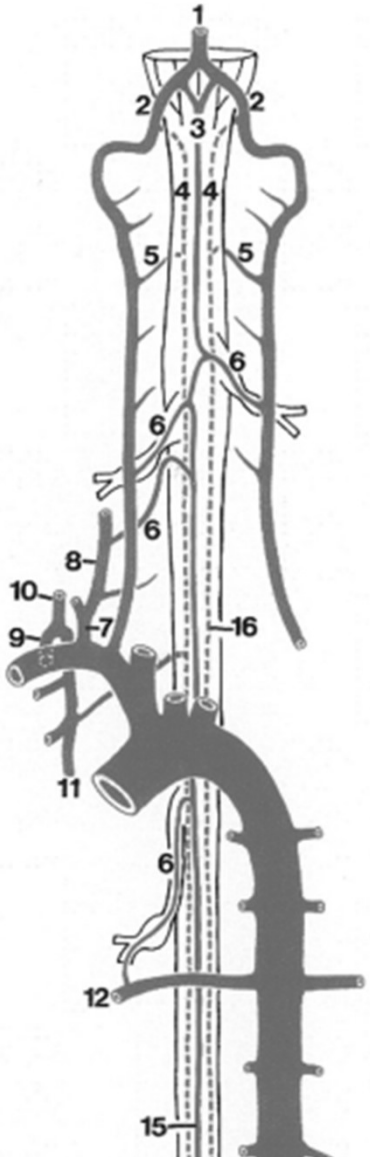

1. Basilar artery
2. Vertebral artery
3. Anterior spinal artery
4. Posterior spinal artery
5. Radiculo-pial artery
6. Anterior radiculo-medullary artery
7. Thyro-cervical trunk
8. Cervical ascending artery
9. Costocervical trunk
10. Deep cervical artery
11. Supreme intercostal artery
12. Intercostal artery
13. Arteria radicularis magna (of Adamkiewicz)
14. L5 anterior radiculo-medullary artery (of Desproges-Gotteron)
15. Anterior arterial spinal axis
16. Posterior arterial spinal axis

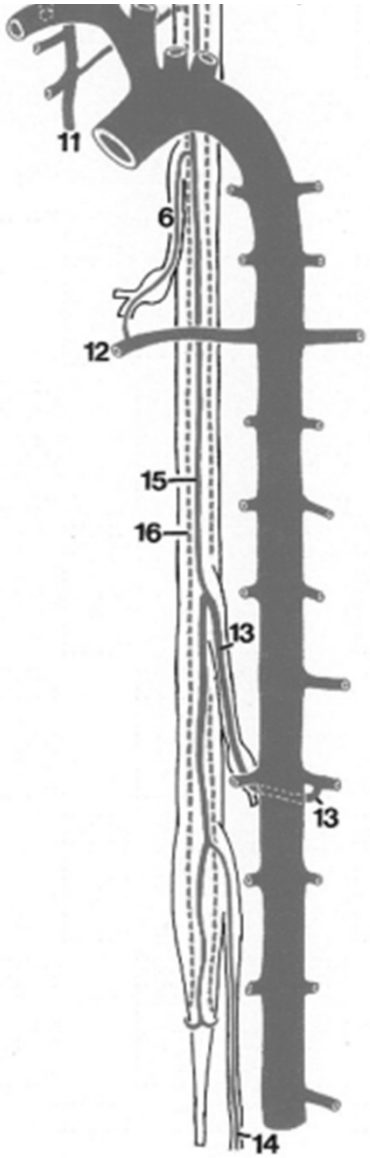

IRRIGAÇÃO ARTERIAL MEDULAR

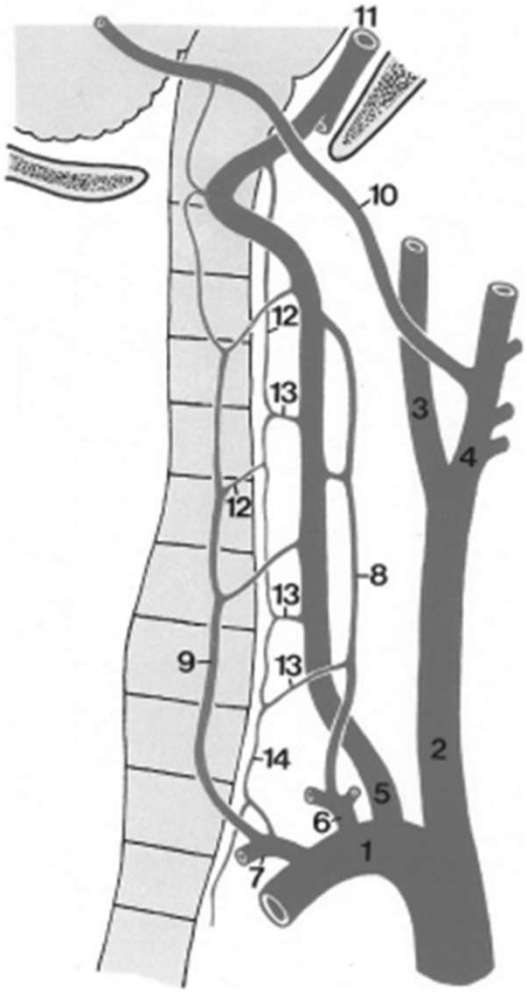

1. Sub-clavian artery
2. Common carotid artery
3. Internal carotid artery
4. External carotid artery
5. Vertebral artery
6. Thyro-cervical trunk
7. Costocervical trunk
8. Cervical ascending artery
9. Deep cervical artery
10. Occipital artery
11. Basilar artery
12. Anterior spinal artery
13. Anterior radiculo-medullary artery
14. Anterior arterial spinal axis